

# Bitendinous Palmaris Longus Muscle: A Case Report

JANANI MAHESHWARI V VYAS<sup>1</sup>, SENTHIL KUMAR SAMPATH KUMAR<sup>2</sup>

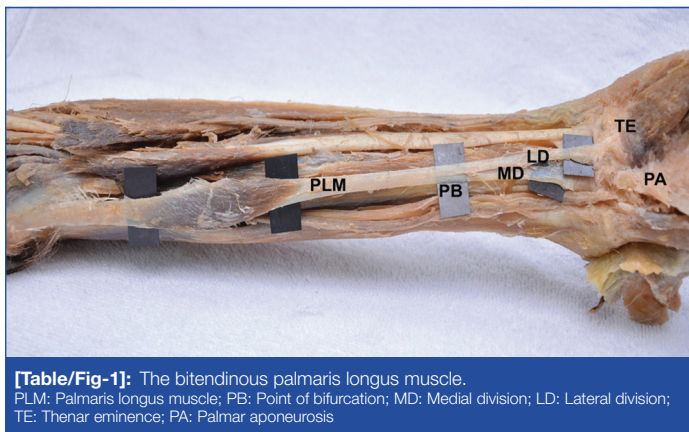
## ABSTRACT

Palmaris Longus Muscle (PLM) is one of the common flexor muscles of the forearm. Classified as a phylogenetically retrogressive muscle, it often exhibits anatomic variations such as agenesis and variation in location, morphology and attachment. A Bitendinous PLM was identified in a female cadaver on the left side; the tendon of insertion bifurcated into lateral and medial tendons and inserted into the base of the Thenar eminence and Palmar aponeurosis, respectively. The lengths of the muscle and the tendons of insertion, the point of bifurcation and width were measured. PLM tendon is highly valued as an ideal donor for tendon grafts. The knowledge of such a variant will benefit anatomists, hand surgeons, orthopaedicians and plastic surgeons.

**Keywords:** Graft, Incidence, Reconstructive surgery, Tendons, Tendon transfer

## CASE REPORT

During routine dissection, a bitendinous PLM was encountered on the left extremity in a female cadaver. Right PLM was normal. Vernier caliper and scale were used to perform the morphometry of the muscle. With a tendinous origin of 6 cm (length) from the medial epicondyle of the humerus to the proximal muscle belly (measuring 7.2 cm in length), the Palmaris longus tendon bifurcated on its course towards insertion. The point of bifurcation of the tendon of insertion was at 6.7 cm from the distal end of the muscle belly. From the point of bifurcation, the medial division merged with the distal margin of the Flexor retinaculum and the Palmar aponeurosis, normally. The lateral division inserted into the base of the Thenar eminence [Table/Fig-1]. The length of the lateral and medial divisions of the tendon from the point of bifurcation till insertion was 7 cm and 6 cm, respectively. The length of the tendons of insertion, therefore, was 13.7 cm (with the lateral division) and 12.7 cm (with the medial division). Hence, the total length of the PLM with the lateral and medial divisions was 26.9 cm and 25.9 cm, respectively. The tendon of insertion narrowed in width towards the insertion; the width of the tendon at the distal end of the muscle belly was 0.9 cm, 0.7 cm at the point of bifurcation and both lateral and medial divisions measured 0.5 cm from bifurcation till insertion.



**[Table/Fig-1]:** The bitendinous palmaris longus muscle.  
PLM: Palmaris longus muscle; PB: Point of bifurcation; MD: Medial division; LD: Lateral division; TE: Thenar eminence; PA: Palmar aponeurosis

## DISCUSSION

The PLM arises from medial epicondyle of the humerus as a short muscle belly with the common flexor origin; its long slender tendon passes superficial to the transverse carpal ligament and is attached to the distal half of its anterior surface and centrally to the Palmar aponeurosis. This case report presents the features of a PLM that

exhibited a tendinous origin followed by a short muscle belly and a bifid tendon of insertion with the medial tendon following normal insertion and the lateral one inserting into the base of the thenar eminence. PLM, a weak flexor of the wrist, exhibits interesting variants being the most variable muscle in the body [1] recording an agenesis of 10%. Among vertebrates, it is restricted to mammals (ruminants, pachyderms, rodents and carnivores) and its absence among higher apes (primates) [2,3], but, its presence in lower groups suggests retrogression due to gradual development of prehension [4,5]. It is best developed when the forelimb performs a weight-bearing role. The variations of PLM were classified as: Complete agenesis; Variation in location, Form of the fleshy portion; Aberrancy in attachment at either extremity; Duplication or triplication; Accessory slips; Replacing elements of similar form or position [6].

Its insertion shows high variability. Upon examination of 530 forearms, the incidence of variations in form of PLM was 9%, of which bifid muscle belly or tendon or both were recorded [6]. The insertion may be augmented by accessory slips or may totally attach to the fascia of the thenar eminence. Antebrachial, thenar, hypothenar fasciae and muscles, carpal bones, long flexor tendons, flexor carpi ulnaris, transverse carpal ligament, interosseous membrane are the structures that a slip of the distal bifid tendon might insert into [6]. Earlier reports of variant insertions have been mostly among males [7,8] and more on the right side [7-9]; the current case is that of a female and found in the left upper limb.

Few earlier studies have also reported the lateral slips from the superficial or lateral divisions of the tendon inserting into the base of the abductor pollicis brevis muscle or the thenar eminence [8-10]. The medial division in the present case inserted into the palmar aponeurosis similar to the superficial medial slip reported by Mathew AJ et al., [11].

While a thenar insertion, similar to our case, can aid stronger abduction of the thumb, the opinion is that the possibilities of Median nerve compression are higher [12]. Histologically and developmentally Palmaris longus and Palmar aponeurosis arise independently and do not share a common origin, thus, explaining the variation in attachment areas [13].

In a novel attempt to estimate the length of the Palmaris longus tendon, before attempting to harvest it, the relationship between the length of the PLM tendon and the lengths of the forearm and hand was studied and was found to have a direct significant moderate relationship [14]. The analysis confirmed that with every increase of one millimeter in the length of hand, the length of Palmaris longus

increases by 0.734 mm, based on which a series of predicted lengths of PLM tendons were presented for particular length of hand. The Mean ( $\pm$ SD) length and width of PLM tendon was found to be  $162\pm 19.5$  mm and  $4.7\pm 1.2$  mm, respectively. The width of the tendon had no significant relationship with the length of the forearm, hand, wrist width and circumference. Another study [15] reported the average length of PLM to be 26.9 (2.6) cm within a range of 22.5-31.5 cm, the PLM tendon was 13.1 (3.3) cm in length (range: 8-15.5 cm) and the Muscle belly measured 9.5-23 cm long. In comparison, the length of the PLM in the current case and its tendons is identical with the latter [15] but, for the muscle belly. Yet another bifurcated left PLM tendon had similar insertion and dimensions as the current case [7].

The Schaeffer's test alone helps detect the presence of a V-shaped bifid PLM tendon in the living; this was further confirmed by ultrasonography [10]. Such a tendon, similar to the case being presented, is expected to serve specific purposes as a graft, in which regard one needs to consider the point of bifurcation. In the current case, the point of insertion of the medial division at the distal end of flexor retinaculum was taken as a point of reference to measure the point of bifurcation and not the interstyloid line. However, the point of bifurcation in the current case did not fall over the line of crossing of the PLM tendon over the median nerve, thereby, minimizing the possibility of damage or injury to the Median nerve during excision/ablation for graft. This was unlike the report by Olewnik L et al., where the Median nerve crossed 31.6 (7.2) mm to the interstyloid line and the lateral (mean length of 39.7 mm) and medial (mean length of 26.5 mm) divisions inserted into the Palmar aponeurosis and into the flexor retinaculum, respectively [16]. The authors also proposed a new classification of the PLM and its variants in relation to the median nerve, the type II (10 out of 80 limbs) of which, had the PLM tendon bifurcating above the line of Median nerve crossing the Interstyloid line at 32.9 (1.4) mm [16]; the case being discussed may probably be classified as a variant of this type. Alike the current case, there are reports of bitendinous PLM bifurcating, well away, 9 cm, from the wrist [8], also not in much proximity to the median nerve. Few workers [16] opine that in the case of a bifid PLM tendon, care has to be taken while excising for graft purposes due to the risk of tendon tearing at the point of bifurcation. Another classification of PLM was recently proposed based on its anatomical and clinical importance [17], but, the authors had not come across PLM with a bifid tendon of insertion.

The distal strip of Palmar fascia is used to lengthen the PLM tendon which is then transferred subcutaneously to the tendon of insertion of Abductor Pollicis Brevis for augmentation of thumb elevation from the palm and facilitate the duplication of opposition. This has been successful in cases of carpal tunnel syndrome with thenar atrophy, injury to thenar muscles and direct trauma to the Median Nerve in the forearm [18].

Myological study reveals that the tensile strength, width and toughness of palmaris longus tendon permits it to be split into strips to provide more length during ptosis correction. It is cable-like, unnoticeable and glides smoothly through tissues, hence, minimizing surgical trauma and post-operative complications and recurrence in the long run. It is fully developed by birth and hence, autogenous

PLM tendon is recommended [19] as a frontalis suspension material for correcting congenital ptosis with poor levator function in pediatric patients below 3 years of age, as an effective alternative to Fascia lata. Its superficial location and morphology renders it an ideal donor tendon for lip augmentation [20], ptosis correction, management of facial paralysis [21], opponensplasty and replacement of the tendons of hand and fingers.

## CONCLUSION

Thus, a bitendinous PLM is of interest to anatomists in teaching and making medical students aware of the possible morphological variations of muscle. In addition, the knowledge of its feasible dimensions is of importance to hand surgeons, ophthalmologists and orthopaedicians who can certainly consider harvesting the tendon for reconstructive surgical purposes.

## REFERENCES

- [1] Bryce T. Quain's Elements of Anatomy. 11<sup>th</sup> ed. London: Longmans, Green; 1923.
- [2] Kohlebrugge JH. Muskeln und peripheren Nerven der Primaten. Verhandl. Der Konink. Akad. Wet., Amsterdam. 1897. p. Sect.2, Bd.5, S.246.
- [3] Keith A. On the Chimpanzees and their relationship to the Gorilla. Proc Zool Soc London. 1899;296-314.
- [4] Humphry G. The muscles of vertebrates. J Anat Physiol. 1872;6:293-376.
- [5] Le Double A. Traite des Variations du System Musculaire de L'Homme. Schleicher, Paris. 1897.
- [6] Reimann AF, Daseler EH, Anson BJ, Beaton LE. The palmaris longus muscle and tendon. A study of 1600 extremities. Anat Rec. 1944;89(4):495-505.
- [7] Sunil V, Rajanna S, Gitanjali, Kadaba J. Variation in the insertion of the palmaris longus tendon. Singapore Med J. 2015;56(1):e7-9.
- [8] Iqbal S, Iqbal R, Iqbal F. A bitendinous palmaris longus: Aberrant insertions and its clinical impact-A case report. J Clin Diagnostic Res. 2015;9(5):AD03-AD05.
- [9] Kumar N, Patil J, Swamy RS, Shetty SD, Abhinitha P, Rao MK, et al. Longus: a unique variation of a retrogressive muscle. Ethiop J Heal Sci. 2014;24(2):175-78.
- [10] Alshaham AA, Mular P, Jawad K. Anomalous V-shape palmaris longus tendon : two cases. J Med Cases. 2010;1(2):68-70.
- [11] Mathew AJ, Sukumaran TT, Joseph S. Versatile but temperamental: A morphological study of palmaris longus in the Cadaver. J Clin Diagnostic Res. 2015;9(2):AC01-AC03.
- [12] Kumar V, George BM. An unusual palmaris longus tendon: variation in the insertion and orientation at the level of wrist joint. Int J Anat Var. 2009;2(2):138-39.
- [13] Caughell KA, McFarlane RM, McGrouther DA, Martin AH. Developmental anatomy of the palmar aponeurosis and its relationship to the palmaris longus tendon. J Hand Surg Am. American Society for Surgery of the Hand. 1988;13(4):485-93.
- [14] Manohar A, Rampal L. Novel method to estimate the length of the palmaris longus tendon. Malaysian J Med Heal Sci. 2013;9:19-24.
- [15] Stecco C, Lancerotto L, Porzionato A, Macchi V, Tiengo C, Parenti A, et al. The palmaris longus muscle and its relations with the antebrachial fascia and the palmar aponeurosis. Clin Anat. 2009;22(2):221-29.
- [16] Olewnik Ł, Wysiadecki G, Polguy M, Podgórski M, Jezierski H, Topol M. Anatomical variations of the palmaris longus muscle including its relation to the median nerve-A proposal for a new classification. BMC Musculoskelet Disord. 2017;18(1):15-17.
- [17] Georgiev GP, Iliev AA, Dimitrova IN, Kotov GN, Malinova LG, Landzhov B V. Palmaris longus muscle variations: clinical significance and proposal of new classifications. Folia Med (Plovdiv). 2017;59(3):289-97.
- [18] Braun RM. Palmaris Longus tendon transfer for augmentation of the thenar musculature in low median palsy. J Hand Surg Am. 1978;3(5):488-91.
- [19] Lam DSC, Ng JSK, Cheng GPM, Li RTH. The use of autogenous palmaris longus tendon as a sling material for ptosis correction in children. Am J Ophthalmol. 1998;126(1):109-15.
- [20] Davidson BA. Lip augmentation using the Palmaris longus tendon. Plast Reconstr Surg. 1995;95(6):1108-10.
- [21] Atiyeh BA, Hashim HA, Hamdan AM, Kayle DI, Musharafieh R. Lower reconstruction and restoration of oral competence with dynamic Palmaris longus vascularised sling. Arch Otolaryngol Head Neck Surg. 1998;124:1390-92.

### PARTICULARS OF CONTRIBUTORS:

1. PhD Scholar, Department of Anatomy, Sri Ramachandra Medical College and Research Institute, Porur, Chennai, Tamil Nadu, India.
2. Professor, Department of Anatomy, Sri Ramachandra Medical College and Research Institute, Porur, Chennai, Tamil Nadu, India.

### NAME, ADDRESS, E-MAIL ID OF THE CORRESPONDING AUTHOR:

Dr. Senthil Kumar Sampath Kumar,  
Professor, Department of Anatomy, Sri Ramachandra Medical College and Research Institute,  
Porur, Chennai-600116, Tamil Nadu, India.  
E-mail: ssksrmc@gmail.com

FINANCIAL OR OTHER COMPETING INTERESTS: None.

Date of Submission: **Jan 24, 2018**  
Date of Peer Review: **Mar 12, 2018**  
Date of Acceptance: **Aug 21, 2018**  
Date of Publishing: **Nov 01, 2018**